

## **Periparturient diseases in the mare: Management and Prevention**

### **Insights inside the Foaling Mare**

J.Govaere, M.Hoogewijs, A.de Kruif

*Fac. Veterinary Medicine, Dep. Reproduction, Obstetrics and Herd health,*

*Ghent University, Belgium*

*Jan.govaere@ugent.be*

5

### **Introduction**

Equine obstetrics presents a complex and challenging knowledge domain to both breeders and veterinarians. The foaling process is usually swift and smooth. Abnormal conditions require efficient diagnostic and intervention skills and the mastery of a broad knowledge base in order to explain and handle emergency situations (Schmid et al. 1994).

Due to the seasonality in equine breeding management, obtaining experience without a good initial insight into the different possibilities of dystocia, with its inherent three dimensional aspects, is difficult. Previous experience in bovine obstetrics is very helpful to get sufficient skills in intra uterine manipulations, especially since only small numbers of obstetrical cases in horses impedes winning experience (Schmid et al. 1994, Frazer 2002). Nonetheless, there is a need to gain more experience and an increased exposure to routine cases in theriogenology work, especially in large animal species since this represents a significant portion of practice activities. Especially dystocia management is a high priority in a day to day large animal practice (Kustritz et al. 2006). Providing possibilities to ameliorate education in equine obstetrics through animations and movies might be part of a solution to deliver tools for distance learning (Einstein 1997, Govaere et al. 2010).

20

In this article some of the important principles of equine obstetrics are illuminated and discussed.

### **Preparation before foaling**

In order to be certain to attend and assist at the birth of their foals, large stud-farms and veterinary clinics employ experienced staff to observe the mares continuously. This is a very time and labour consuming method resulting in

25

an expensive way of birth control which is not accessible to all horse-owners (Jeffcott and Rossdale 1977, Camillo et al. 2000; Douglas et al. 2002).

30 As a rule, "the best place for the mare's foal is in the foal's mare" until both the mare and foal are ready for delivery (Lopate et al. 2003). In order to predict the foaling date, signs of impending foaling are watched closely by the breeder. Gestation length, relaxation of the sacrosciatic ligaments, filling of the udder, waxing of the teats are helpful signs but are not reliable predictors of the time of foaling (Renton, 1984, Ley et al. 1989).

Lactation will be the final step of reproduction and is essential for breeding success, especially in animals where the placenta doesn't allow transplacental passage of antibodies to the foetus (Jeffcott, 1974). Udder development starts  
35 approximately one month before parturition with a significant increase in mammary size in the last two weeks of pregnancy and a final mammary expansion within 24-48 hours of foaling (Jeffcott and Rossdale 1977; Lopate et al. 2003). Parallel with these udder changes in the peripartum period, there is also an explicit change in the composition of the mammary secretion going from pre-colostrum to colostrum and finally becoming milk. Peaker et al. (1979) were the first to suggest that changes in the concentrations of calcium in mammary prefoaling secretions could be  
40 used to predict foaling. The presuming theory of Peaker et al. (1979) was confirmed by a study of Leadon et al. (1984, 1986) and Ousey et al. (1984). Ousey et al. (1984) were also the first to study the correlation between prefoaling secretions and the foetal readiness. They concluded that, in induced mares, there exists a good correlation between electrolyte concentrations in prefoaling secretions and foetal maturity. A variety of tests and test kits is now available to analyze prefoaling mammary secretion (Ousey 1984, Cash et al. 1985, Ousey et al. 1989, Ley et al.  
45 1993, Semacan et al. 1999, Douglas et al. 2002).

Well before calcium rises in parturition secretions, manipulations that may cause much stress should have been performed by now (e.g. unshoeing) and when electrolyte changes have become obvious, vulvoplasty sutures should be opened.

Although the incidence of dystocia is low, varying from 4-20% depending on the breed (Vandeplassche et al. 1980),  
50 it remains a major clinical challenge because of the explosive nature of the equine parturition (Bucca 2006). The fact that the length of time between the rupture of the chorioallantoic membrane and birth has a profound effect on the survival of the foal (Emberson 1992, Frazer et al. 1999, Byron et al. 2002) and the risks of suffocation of the

foal in case of a premature placental separation or red bag delivery (Bucca 2006) emphasize the urgency of a dystocia. To overcome risks of an unattended birth, induction of foaling, when carefully carried out, might, in specific occasions, be an option (Camillo et al. 2000, Chavette-Palmer 2002, Villani and Romano 2008).

Before foaling, the foal's presentation is checked by transrectal ultrasound. In some cases of posterior presentation, an even more careful observation is necessary and induction or C section might be a possible and justified way to handle such parturition in a timely manner. During the transrectal exam attention is paid to the Combined thickness of the uterus and the placenta, diameter of the eye and the echogenity of the foetal fluids, in order to be able to intervene when necessary. Knowledge about the mare's behaviour during and after previous foalings will be useful, especially in breeds where mother behaviour might be questionable. Incompatibility in blood antigens should be checked whenever suspected.

### **Foaling**

The prodromi of the mare are, when left undisturbed, rather obvious; the mare becomes restless and exhibits signs of colic, she switches her tail, urinates small volumes, sweats and she will lie down, rolls over and get up frequently (Blanchard et al. 1995). The normal foaling is preceded with endocrine changes in the late-term pregnant mare. The myometrium is already primed to express oxytocin receptors and as such the uterus has become susceptible and is able to contract forcibly on oxytocin release. Cervical relaxation, and preparation of the whole birth canal, is also a sequel of the endocrine changes. The first stage of labour starts with myometrial contractions, starting at the tip of each uterine horn and progressing caudally towards the cervix, propelling the foetus into the soft dilating cervix. During the first stage of labour, the foal turns from a dorsoventral to a dorsosacral posture with extended forelimbs and head (Jeffcott et al. 1979). The extended forelimbs and head begin their passage through the cervical canal which causes further cervical dilatation (Frazer et al. 1999) (Figure 1). This thrusting movement of the foal's forelimbs ruptures the chorioallantois at the level of the cervical star allowing the escape of allantoic fluid, which is yellow-amber like and of a watery consistency. When the chorio-allantoic bladder, commonly called water bag, is broken, the second stage labour has started. Once the foal is positioned in a correct dorsosacral position, oxytocine is released in a large surge which will lead to the expulsion of the foal in stage 2 (Lopate et al., 2003). Normally the

80 first stage in parturition will take 30 minutes up to 6 hours although the mare is also able to postpone stage 2 when she is disturbed, however most mares will give birth during the night when there is no disturbance surrounding them (Bain and Howey 1975, Blanchard et al. 1995).

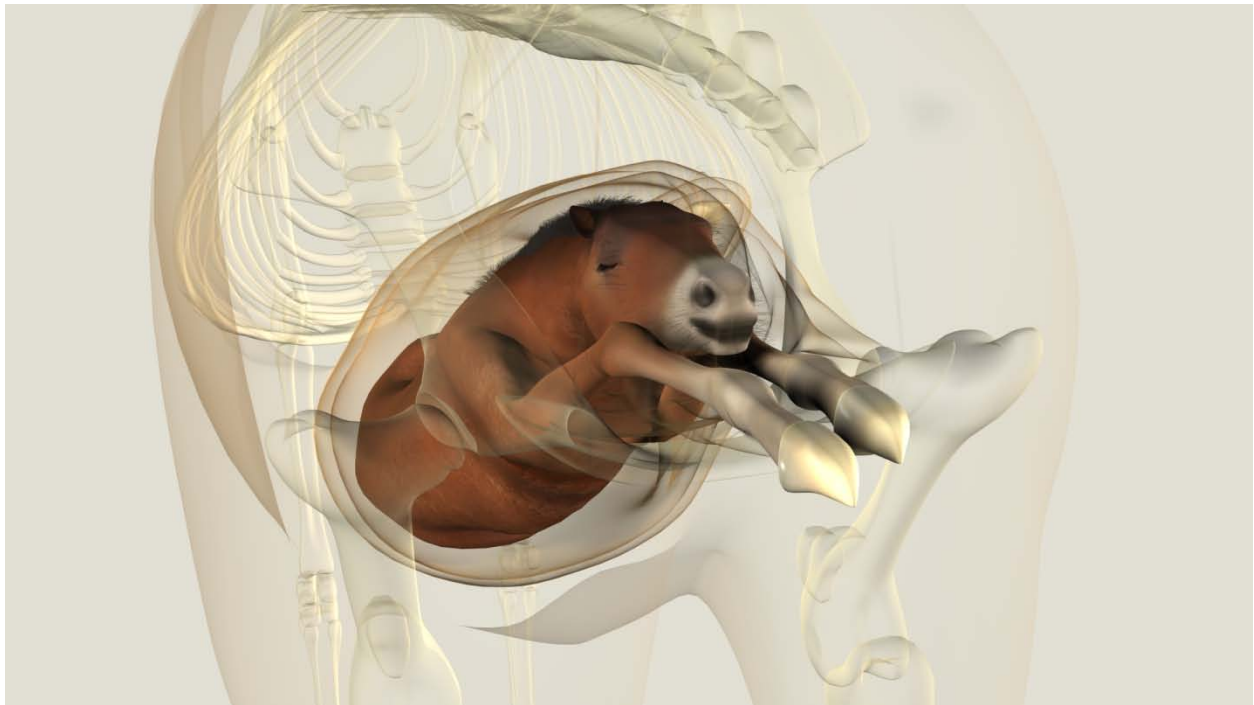


Figure 1. Foal in anterior presentation, dorsosacral position and normal posture.

85 Stage 2 starts when the allantochorion breaks and the amber-coloured water leaks away. The expulsion phase is an explosive process which takes on average only 10-20 minutes (Emberston et al. 1995; Freeman et al. 1999). When undisturbed, the mare will lie down in lateral recumbency and active abdominal contractions are obvious. The presence of the foal inside the pelvic canal will induce more oxytocin and prostaglandin release and as such stimulates uterine and abdominal contractions. Shortly after 'the water breaks', the white-bluish amnion sac will appear at the vulvar lips (Ginther and Williams 1996). The allantochorion breaks at the level of the cervical star and  
90 remains attached to the endometrium until after foal expulsion.

Premature placental separation is an abnormal presentation of the placenta where the cervical star has failed to rupture. Instead of the white bluish amnion, the red velvet-like chorion is presented. This presentation demands immediate intervention and delivery of the foal (Rossdale and Ricketts 1980, Blanchard et al. 1995). The foal should be treated in these conditions as if it was hypoxic.

95 At the start of second stage labour the dam is still standing. The non ruptured amniotic sac appears at the lips of the vulva. The amniotic sac has a fairly thick transparent white-bluish coloured membranous outer cover that will allow visualisation of the front legs. Once the head of the foal has entered the pelvic canal, the mare will lie down in lateral recumbency and the abdominal straining begins. Strong abdominal contractions push the foal throughout the birth canal. One front foot of the foal is normally about 15 cm in front of the other (Figure 2). In this way the width of the foal at the shoulders is reduced as it passes through the pelvic canal. The nose of the foal, which lies upon the carpi, appears very soon after the feet, and abdominal contractions continue until the front legs, head, neck and thorax of the foal have been expelled (Frazer et al. 1999). At this time the amniotic sac normally ruptures and the foal starts breathing. Then contractions will restart and continue until the foal is completely expelled except for its hind legs which remain within the dam's vagina. Now the second phase is completed and the dam and the foal better  
100 stay in this position for a while.  
105

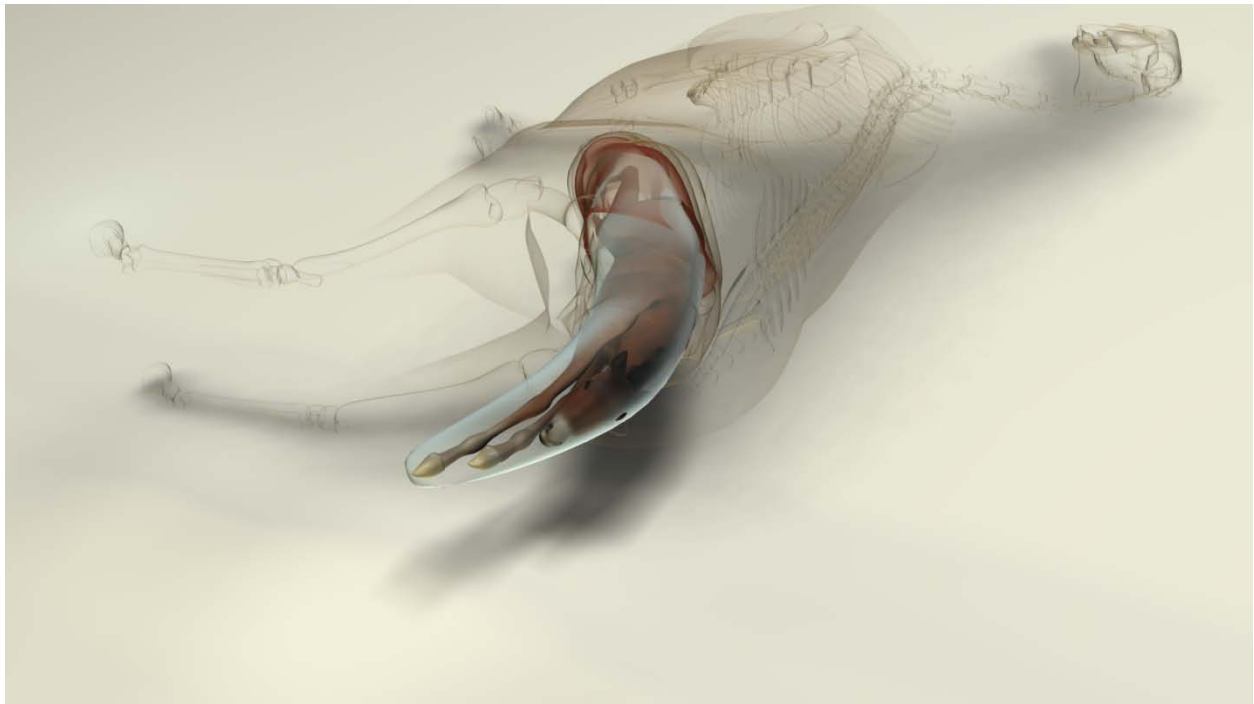


Figure 2. One front foot of the foal is normally about 15 cm in front of the other.

Malposture or malposition of the foal may cause a delay in the birth process. A delay of more than 15 minutes between leakage of the water and appearance of the amnion sac or the absence of strong abdominal contractions after rupture of the chorioallantois requires a vaginal palpation in order to evaluate the progress in the birth process.  
110

Whenever the reddish chorionic side of the allantochorion should present itself at the vulvar lips intervention is imperative. A malposture, the presentation of only one foot, two feet without a head, or the head alone, logically requires immediate intervention of the obstetrician (Frazer et al. 1999).

115 When the mare gets to her feet after the expulsion of the foal, the umbilical cord will rupture. To prevent the mare from tearing the afterbirth by standing on it, the afterbirth is tied up. A large part of the dams diffuse placenta has become detached by the end of second stage labour. It's pushed caudally into the pelvis by the continuation of the uterine contractions and the involution of the uterus. As the placenta is more firmly attached to the endometrium in the non-pregnant horn, great parts of the placenta of the pregnant horn and corpus may be seen hanging out the vagina while the placenta is still attached in the non-pregnant horn. Once in the pelvic canal, the mare will lie down  
120 and abdominal straining will be seen during this 'active' expulsion of the placenta. The placenta is then expelled inside out, with the grey allantoic surface of the allantochorion outermost. Most mares will expel their placenta within 1 hour (Provencher et al. 1988, Sevinga et al., 2004).

If the placenta remains longer than 6 hours post partum, secondary problems are more likely to occur. Prevalence and severity of the sequela is dependent on breed and might result in devastating outcomes (Frazer, 2003; Sevinga  
125 et al., 2004). One of the most frightening consequences is the metritis septicaemia laminitis condition which is breed related with a high incidence in heavy draft breeds (Govaere et al. 2008). When the inflammation involves the laminae of the hooves, this may quickly lead to a life threatening situation for the mare.

### **Dystocia**

In 'normal sized' horses the prevalence of dystocia is minimal and around 4%, however in small breeds (e.g.  
130 Shetland) and heavy draft horse breeds, dystocia might vary from 8 to 20% (Vandeplassche et al. 1980, Campbell 1992). Mostly the foals will be born in an anterior presentation (98, 8%) and will only cause dystocia in about 3% of cases. The long foetal extremities are more prone to provoke malpostures when compared to cattle (Pascoe 1981, Vandeplassche 1993, Frazer et al. 1997, 1999). In these cases, a reflected head is the most prevalent reason of dystocia and can be corrected by reposition (27%) or after a partial foetotomy (65%) and will only have to be  
135 delivered by section caesarea (SC) in a minority of cases (8%) (Vandeplassche et al., 1980). Posterior presentations,

although seldom seen, will cause more difficulties during parturition. Transverse presentations, with the ventral transverse most commonly encountered, are rare but will give cause to dystocia.

Improved protocols in how to handle mares in dystocia and improved access to high quality surgical facilities have lead to better prognosis and results over years, but economic limitations will often force the veterinarian to perform a (partial) foetotomy. In heavy draft mares, not only financial limitations but also medical difficulties (e.g. inadequate perfusion and oxygenation during general anaesthesia) might be reason to perform a (partial) foetotomy instead of a caesarean section.

A successful delivery by C-section can only be achieved when a quick and ready access to clinical facilities is available. However, when C-section is used as last option when all other ways have been unsuccessful, results will be very disappointing. Once the allantochorion is broken, the foal should be born without delay. Any loss of time will lead to placental separation and will compromise severely chances on a successful outcome. An equine obstetrician should have all skills to correct any '*normal abnormalities*' and should be able to discern any condition that needs to be referred to a clinic in order to optimize the success rates.

Although resolving malpostures and malpositions still relies on 'old fashion' reposition techniques nowadays they can be taught in a 'better, modern and innovative fashioned way' (Govaere et al. 2010).

The groom should be taught that whenever a dystocia is suspected that it is best to keep the mare standing /walking until obstetrical help arrives. An adequate restrain of the dam is essential when trying to deliver a maldispositioned foal. The use of a twitch, adequate help and an area with clean and soft bedding, are essential. Tranquillisation of the mare will exert an effect on the foal as well and is better avoided when trying to extract a life foal. When inevitable, light sedation, using acetylpromazine or xylazine, can be used (LeBlanc and Norman 1992). Epidural anaesthesia will reduce the vaginal sensitivity and as such impede the Ferguson reflex, but will not stop the uterine or the abdominal contractions (LeBlanc and Norman 1992, Frazer et al. 1999). The possibility to use tocolytic drugs is an advantage in dystocia management.

The preparation of the mare (tail wrap, thoroughly cleaned perineum and disinfected clinicians arm) and adequate lubrication (oil based) are essential to start with (Ley 1989, Frazer et al. 1999). A thorough check for lesions and lacerations, control of the degree of opening of the birth canal, evaluation of the disposition of the foal and the foals

viability together with an estimation of the foals size, should be done and, in posterior presentation, when dealing with a life foal, the course of the umbilical cord should be checked as well (Frazer et al. 1999, Govaere et al. 2010b).

Active foetal responses can make even a simple maldisposition a difficult one to correct. Especially retraction of the foetal head may create a reposition of a lateral deviation almost impossible. A rope *snare* behind the ears through the mouth can prevent this to happen (Frazer et al. 1999).

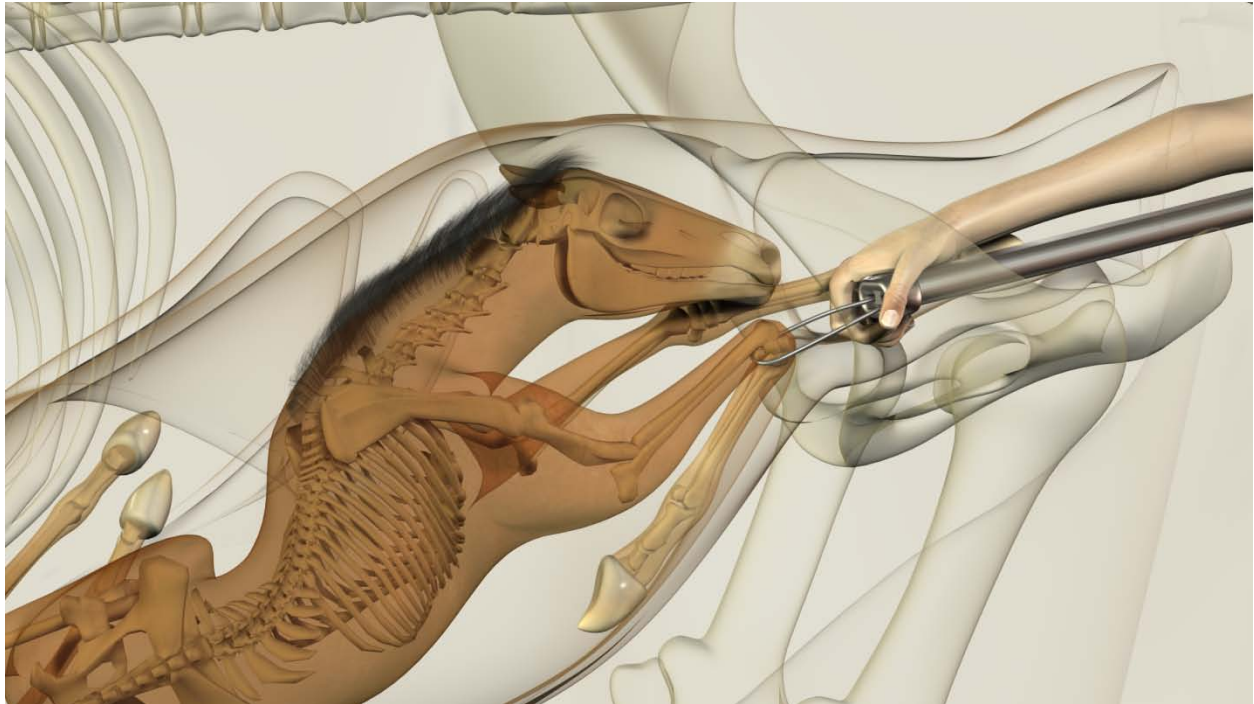
The method of delivering a mare in dystocia is dependent on, and influenced by, the presence of a life foal, the clinician's skills, available equipment and personnel and financial constrains of the owner (Frazer et al. 1999). A foetotomy should not be avoided by an experienced veterinarian when indicated. Main goal of a foetotomy is preserving the mares' life and future fertility (Ley 1994).

Describing the techniques of mutation, the manipulation of the foal to return to a normal presentation, position and posture (Roberts 1986) is beyond the scope of this article and readers are referred to the extensive paper by Frazer et al. (1999), only the basic principles are repeated in this paper. In short the mutation consists of a combined action of repulsion, rotation, adjustment and extension of extremities. Over enthusiastic attempts by inexperienced obstetricians is one of the most prevalent causes of uterine bruising and rupture (Frazer et al. 1999). Extra space in those cases can be obtained by placing the hindquarters high and instillation of lubricant into the uterus. When the uterus is contracted, a uterus spasmolythicum should be used before an attempt is made to repulse the foal. Whenever traction is applied, this should be done in concert with the normal expulsion forces of the mare and, in between straining movements of the mare, traction should be seized. Eventually a short term general anaesthesia in Trendelenburg position can be performed in order to correct a difficult posture. When doing so the mare can be prepared for surgery during the manipulations of the obstetrician and a caesarean section can be done as soon as it becomes obvious that a timely correction is not feasible. The prognosis for foal survival is strongly dependent on interval between initiation of phase 2 and delivery of the foal and in general when C-section is used in dystocia management success rates will not exceed 30% (Embertson et al. 1995, Abernathy et al. 2009).

Mutation can be even more difficult to perform when the foal is dead. When dealing with limb contractures a partial foetotomy or caesarean section might be the only possible way to deliver the mare (Giles et al. 1993, Hong et al. 1993) (Figure 3). Prognosis of mutation for mare and foal as well as prognosis after foetotomy and caesarean section



are dependent on available skills and equipment besides the time of duration of the procedure and the malposition that had to be dealt with.



190

Figure 3. A partial foetotomy might be a possible way to deliver the foal in cases of dystocia caused by limb contractures

### **Postpartum care of the mare**

When the mare foaled without any complications, usually the first day after parturition a brief clinical check up of the mare is advised. When mare-foal bond is well established, the udder the perineal region and rectal temperature is checked (Asbury 1993). An extended gynaecological examination in these cases can be delayed until foal heat in order not to disturb the mare-foal bond (Frazer 2003).

195

During stage 3 of parturition, uterine contractions continue and might cause mild symptoms like colic in the post partum mare. In some cases these contractions might lead to excesses as inversion and prolaps of the uterus or vesicae, or even to a rectal prolaps. Secondly, the release of the foal, placenta and foetal fluids causes a void in the abdomen which might lead to a translocation of the intestines (esp large colon). Other causes of colic in the post partum period include pneumo uterus, haematoma in the broad ligaments, bruising of the colon or rupture of the caecum or vesicae, uterine rupture and peritonitis. Of all mares referred to the clinic for postpartum emergencies,

200

hemorrhage of the urogenital tract (16.6%) and large colon volvulus (15.9%) were the most prevalent reasons for surgery (Dolente et al., 2005). Complications, besides the fistula and cloaca formations, are more frequently seen in  
205 older multiparous mares or when giving birth to large foals (Livesey and Keller, 1986). Postpartum complications may occur in every mare despite the progress of the parturition, although in 25% of referred cases for postpartum complications a dystocia condition preceded the complication (Dolente et al. 2005).

A correct and quick diagnosis is sometimes hard to make since signs may be subtle and hard to distinguish depending on degree and variety of lesions and because maternal behaviour of the mare may disguise or impede  
210 externalization of pain symptoms (Frazer et al., 1997, 2003; Dolente 2005). Peritoneal fluid analysis can help discern the cases suited for conservative therapy vs those that do need imminent surgery (Frazer et al., 1997, Frazer 2003). Endometritis will be present in almost every dystocia case and should not be neglected.

### **Inversion/prolapse of the uterus**

A large part of the dams diffuse placenta has become detached by the end of second stage labour. It's pushed  
215 caudally into the pelvis by the continuation of the uterine contractions and the involution of the uterus. As the placenta is more firmly attached to the endometrium in the non-pregnant horn, great parts of the placenta of the pregnant horn and corpus may be seen hanging out the vagina while the placenta is still attached in the non-pregnant horn (Frazer, 2003). Uterine inversion and prolapse in the mare is likely to be related to the expulsion of the foetal membranes which tend to separate from the endometrium much more readily in the uterine body but seem to be  
220 more firmly attached at the horns, particularly the tips.

As the placenta in the tips of the horns, especially the non pregnant horn, stay attached to the endometrium while it becomes detached in the uterine body, the weight of the placenta will pull at the uterus. This traction may cause inversion of the uterine horns. The continual uterine contractions, and the subsequent straining as the mass of the foetal membranes together with the inverted uterus enters the pelvis, cause the whole of the uterus to be inverted and  
225 prolapsed. And so turn into a life threatening situation for the dam. Excessive tension to the placenta in attempt to remove the foetal membranes might induce an inversion and prolaps as well (Perkins and Frazer 1994; Lopate et al. 2003).

Mares suffering an inversio of the uterus will have in most cases a history of retained foetal membranes, a foetal extraction prior to complete relaxation of the reproductive tract, a too forceful or too fast extraction of a foal, a  
230 prolonged, difficult dystocia, vaginal or vulvar lacerations or ruptures in mesorectum or uterus. Also cases of abortion and older mares with a poor body condition are vulnerable to the condition.

In order to prevent the condition, it is imperative to minimise irritation in the pelvic canal as soon as possible. For example; insertion of ice packs after a forceful extraction is cheap and easy way to prevent swelling and achieve normalisation of bruised tissues in the pelvic canal.

235 In cases of retained foetal membranes, it is imperative to tie up the placenta to prevent the mare stepping on it (Lopate et al., 2003). An aggressive manual removal might provoke an inversion and promotes micro retention of villi into the endometrium crypts and is not advisable.

Diagnosis of an inversion is made based on history of the mare and rectal and vaginal palpation. Colic, nonresponsive to analgesics and sedatives, in a post partum mare is a common presenting sign. On rectal palpation, a  
240 blunt ending uterine horn might be in reach and a tensed ligament will be torn into the blunt ending cranial part of the uterine horn. On vaginal exploration, the inversion will be easy to recognise in the (previously non-pregnant) uterine horn. The further the invagination reaches, the more tension will be exerted to the ligaments and even more pain will increase. Once the invagination leads to a prolapsed uterus, diagnosis is obvious. Mares with a uterine prolaps will develop shock as result of ischaemia and endotoxemia. Once the uterus is prolapsed beyond the level of  
245 the hocks, rupture of the arteries and a rapid death can occur.

An inversion without prolaps is best treated in the standing mare (if possible with elevated hind quarters) after injection of a uterus spasmolyticum. Once the uterus is relaxed, the tip of the inverted horn can be gently pushed cranially. If the arm of the operator is not long enough to reach the cranial part of the horn, filling the uterus with saline will be helpful. Also, a clean blunt object, like a bottle, can be used for this purpose. When dealing with a  
250 prolapsed uterus, mares are best treated without the use of sedatives if possible (otherwise the use of an  $\alpha_2$  agonists is most advisable) and replacement of the uterus, after cleaning and careful examination, will be more easy after a epidural anaesthesia. The replacement is often done the 'double bag-way' with copious amounts of lubricant in the

standing mare with elevated hindquarters. Non steroidal drugs, antibiotics and oxytocin will be given to the mare after resolving the condition. Endometritis is an almost non avoidable sequel of this condition.

255 As always the foetal membranes should be checked meticulously after they are expelled (Frazer, 2003). In cases of delayed separation, this might be a difficult burden. The study of the epitheliochorial diffuse microcotyledonaria placenta of the horse is essential and useful first of all in order to assess what the foal has experienced during late pregnancy and parturition, secondly in order to prevent and anticipate life threatening risks for the foal and mare, and lastly in order to advise measurements for future pregnancies (Whitwell and Jeffcott, 1975). In cases of delayed  
260 placental separation prompt, appropriate therapy should be initiated in order to avoid more serious complications and to preserve future fertility of the mare (Blanchard et al. 1990, Perkins and Frazer 1994).

### **Uterine rupture**

In about 5.5% of the post partum emergencies cases, uterine rupture is involved (Dolente et al. 2005). Rough manipulations during repositions or foetotomy (Perkins and Frazer 1994; Frazer et al. 1999), dropsy of the foetal  
265 sacs, manipulations of an oedematous wall in cases of uterine torsion might cause uterine rupture (Wheat and Meagher 1972, Martens et al. 2009). Although, even spontaneous ruptures of the uterine wall have been described (Honnas et al. 1988) and these all may cause peritonitis. Most tears will occur at the ventral uterine wall and are, when full thickness, prone to cause peritonitis (Lopate et al., 2003). Further examination in the post partum mare is warranted when temperature rises, heart rate increases, increasing depression and diminished milk production is  
270 noticed (Lopate et al., 2003).

If within the reach of the operators arm, ruptures might be sutured with a blind technique, however abdominal exploration will be better in order to assess possible other damage to the intestines (Perkins and Frazer 1994). Since the trauma will have bruised the placenta as well, an examination of the placenta might give a better idea of the localisation of the uterine rupture. In any case, breeding rest for at least 2 months will be mandatory.

### **275 Bladder inversion or prolapsed bladder**

Although not frequently seen, the short, wide urethra of the mare predisposes to an inversion of the bladder (Hackett et al. 1982). In this case the bladder is inverted and the inner surface of the bladder is exposed. The trigonum vesicae might be visible with urine coming from the ureters. In rare cases, intestines will be pushed into the everted bladder.

280 This should be differentiated from a prolapse of the bladder. In this condition the bladder passes through a tear in the vaginal floor and its serosal surface appears in the vulva. Thus the peritoneal surface of the bladder and not its inner surface is visible. The bladder grows as it is filled with urine. If the mare continues to strain, intestines might be forced through the tear in the vaginal floor as well.

These conditions are more frequently seen in draft mares (large diameter of the urethra) and are a consequence of excessive straining during- or post partum.

285 Both treatment of an inversion or a prolapse of the bladder will be easier to perform after an epidural anaesthesia. After emptying and cleaning, the bladder is replaced (through the tear or through the urethra) and the vagina is treated so recurrence cannot occur (suturing of the tear or reconstructing the urethral orifice). Possible sequel after a prolapsed bladder might be urine incontinence.

#### **Haematoma in broad ligament**

290 *During parturition substantial forces are exerted to tissues surrounding the birth canal with possible risk of haemorrhage and rupture of vessels, uterus or gut* (Rossdale 2003). Rupture of the arteria uterine media, utero ovarian arteries or the external iliac artery may occur even before parturition but is, in cases of the a. ut. media, usually associated with an uneventful, fast foaling in an older pluripare mare (Dolente et al., 2005, Ueno et al., 2010). Of all post partum complications referred to hospital, haemorrhage of the urogenital tract is the most  
295 prevalent one and involves about 16.6% of all referred cases in the study of Dolente and co-workers (2005). *Colic signs are exhibited but sometimes only shock precedes death* (Rossdale 2003). For some reason, the Flehmen response is seen in those mares. As long as the serosa surrounding the ligaments can hold the pressure, bleeding can be stopped by the enhancing pressure of the haematoma on the artery defect. Therefore absence of intraperitoneal blood does not exclude a haemorrhage (Rossdale 2003). Once the serosa can no longer withstand the pressure, fatal  
300 blood loss in the abdomen will result in death of the mare. Over enthusiastic diagnostic palpation of the ligaments might stimulate bleeding or rupture (Lopate et al., 2003).

Treatment options are limited since surgery will not allow visualisation and localisation of the source of haemorrhage. All extra stress should be avoided in order to keep the blood pressure low. The benefit of blood

transfusions is not univocal because they cause an increase in blood pressure which might cause more bleeding.

305 Intravenous naloxone and/or formaline have been used to reduce bleeding (Lopate et al., 2003).

### **Intestinal complications post partum**

Rupture of the mesocolon, mesorectum, caecal infarction or bruising of the intestines are rare and most probably caused by circulatory obstruction (infarction) or trauma of the foetal extremities. Portions of the bowel entrapped in the birth canal can be traumatised during stage 2 (Dart et al., 1991). Especially the tip of the caecum is involved in such traumata (Rossdale 2003). Volvulus of the large colon, seen in 15.9% of cases (Dolente et al. 2005), is a frequently encountered complication after foaling when looking at records of referral clinics. In most cases these lesions are seen after dystocia (Dart et al. 1997, Dolente et al. 2005). However when giving an interpretation of the numbers, one had to bear in mind that some more mild or extremely mortal complication will never end up in these case records.

315 When dealing with a rent, mares usually will develop very quickly an increased pulse and respiratory rate and sweating and shock due to severe peritonitis. If 'only' bruising occurs, the mares are presented with colic some days after the foaling. These cases of colic might be partially responsive for analgesics but do develop quite quickly into endotoxaemia and peritonitis. Peritoneal fluid aspiration will show elevated turbidity by enhanced amounts of neutrophils (Livesey and Keller, 1986). Whenever ingestia are found in the abdominocentesis fluid, euthanasia will be the only reasonable 'treatment', in other cases surgical treatment is necessary but the lesions might be difficult to reach. Prognosis is generally guarded.

325 The extraction of the foal, placenta and foetal fluids may cause a void in the abdomen which might lead to a translocation of the intestines such as large colon volvulus. Especially older brood mares are sensitive to colonic torsion during the periparturient period (Rossdale 2003). Clinical signs include severe abdominal pain. Post partum mares are supposed to be more prone to suffer from this condition (Johnston and Freeman, 1997). It is not quite clear if only the place that becomes available post partum is enough to induce a translocation or, since it goes hand in hand with a lowered motility, ileus is more important as trigger to induce a volvulus. If this leads to strangulation, gas distension will be marked and will compromise respiration by direct pressure upon the diaphragm and upon the vena cava. Once torsion has occurred extensive ischaemic damage is likely to develop (Rossdale

330 2003). In this stage, analgesics will not be effective anymore and surgical correction will become urgent. Abdominocentesis results might be inconclusive and moreover they might be hard to perform because of the distended tympanic intestines (Dart et al. 1991). On rectal palpation, a tensed colon filled with gas will become obvious and access to the rest of the abdomen will be inhibited by the distended colon. Prognosis will depend on prompt interference since the rapid deterioration of the condition. Postoperative complications as endotoxaemic shock, protein loss, DIC and laminitis, will make that prognosis on recovery will not exceed 40% (Hance and Embertson 1992).

In the end, it should be emphasized that, although dystocia is always disquieting and worrisome and can have a guarded prognosis for the foal, the mare or the mare's fertility, the vast majority of foalings happen uneventful. Abnormalities must be recognized and corrected as soon as possible bearing in mind the most important principles in dystocia management, being; hygiene, lubricant and protection of the mare's birth canal. In other cases one should diagnose and recognize the ones that cannot be corrected and have to be referred to a hospital as soon as possible in order to guarantee the most optimal outcome for foal, mare and mare's future fertility. Post partum care should emphasize on a regular clinical control of the post partum mare and successful outcome in the event of serious complications is strongly *dependent on the clinician's ability to make a correct diagnosis in a timely manner* (Dolente et al., 2005).

### References

- Abernathy K.K., LeBlanc M.M., Embertson R.M., Pierce S.W. and Stromberg A. (2009). Survival and fertility rates after caesarean section. Proceedings of the AAEP, Las Vegas, USA, Dec 5-8<sup>th</sup>, p 268.
- 350 Asbury A.C. (1993). Care of the mare after foaling. In Equine Reproduction, Eds: A.O.McKinnon, J.L.Voss, Lea and Febiger, Philadelphia. pp 976-980.
- Bain A., Howey W. (1975). Observations on the time of foaling in Thoroughbred mares in Australia. *J. Reprod. Fertil. (Suppl.)* **23**, 545-547.

355

- Blanchard T.L., Martin M.T., Varner D.D. and MacPherson M.L. (1995). Preparation for parturition in the mare. *Veterinary Medicine Equine Practice* 597-604.
- Blanchard T.L., Varner D. and Scrutchfield W. (1990). Management of dystocia in mares: retained placenta, metritis and laminitis. *Comp Cont Educ Pract Vet* **12**, 563.
- Bucca S. (2006 ). Diagnosis of the compromised equine pregnancy. *Vet Clinics N Am- Equine Pract* **22**, 749.
- Byron C.R., Embertson R.M., Bernard W.V., Hance S.R., Bramlage L.R. and Hopper S.A. (2002). Dystocia in a referral setting: approach and results. *Equine Vet.J.* **35**, 82-85.
- Camillo F., Marmorini P., Romagnoli S., Cela M., Duchamp G. and Palmer E. (2000). Clinical studies on daily low dose oxytocin in mares at term. *Equine Vet. J.* **32**, 307-310.
- Campbell M.E. (1992). Selected aspects of miniature horse reproduction; Proc Annu.Mtg.Soc.Therio. Hastings, Nebraska, US, 89-96.
- Cash R.S., Ousey J.C. and Rossdale P.D. (1985). Rapid strip test method to assist management of foaling mares. *Equine Vet.J.* **17**, 61-62.
- Chavette-Palmer P., Arnaud G., Duvaux-Ponter C., Brosse L., Bougel S., Guillome D., Clement F and Palmer E. (2002). Quantitative and qualitative assessment of milk production after pharmaceutical induction of lactation in the mare. *J Vet Med Int Med* **16**, 472-477.
- Dart A.J., Hodgson D.R. and Snyder J.R. (1997). Cecal disease in equids. *Aust Vet J* **75**, 552-557.
- Dolente B.A., Sullivan E.K., Boston R. and Johnston J.K. (2005). Mares admitted to a referral hospital for postpartum emergencies: 163 cases (1992-2002). *J Vet Emerg Crit Care* **15**, 193-200.
- Douglas Brown C.G., Perkins N.R., Stafford K.J. and Hedderley D.I. ( 2002). Prediction of foaling using mammary secretion constituents. *NZ Vet J* **50**, 99-103.



- Einstein, R. (1997). Replacement, reduction and refinement through education, at the University of Sydney. *In* Animal Alternatives, Welfare and Ethics, Developments in animal and veterinary sciences Elsevier science Pub, Amsterdam, The Netherlands vol 27 pp 419-425.
- 385 Embertson R. (1992). The indications and surgical techniques for Caesarean section in the mare. *Equine Vet. Educ.* **4**, 31-36.
- Embertson R.M., Bernard W.V., Hance S.R. and Smith S. (1995). Hospital approach to dystocia in the mare. *Proc. Am. Ass. Equine Pract* **41**, 13-14.
- Frazer G., Burba D., Paccamonti D., Blouin D., LeBlanc M., Embertson R. and Hance S. (1997). The effect of parturition and peripartum complications on the peritoneal fluid composition of mares. *Theriogenology* **48**, 919-931.
- 390 Frazer G.S., Perkins N.R., Blanchard T.L., Orsini J. and Threlfall W.R. (1997). Prevalence of fetal maldispositions in equine referral hospital dystocias. *Equine Vet. J.* **29**, 111-116.
- Frazer G.S., Perkins N.R., Embertson R.M. (1999). Normal parturition and evaluation of the mare in dystocia. *Equine Vet.Educ.* **11**, 41-46.
- 395 Frazer, G.S. (2002). Fetotomy technique in the mare. *Equine veterinary Education Manual* 5 (2002) 33-40.
- Frazer G.S. (2003). Post partum complications in the mare. Part 2: Fetal membrane retention and conditions of the gastrointestinal tract, bladder and vagina. *Equine Vet Educ* **15**, 91-100.
- Freeman D.E., Hungerford L.L., Schaeffer D., Lock T., Sertich P.L., Baker G.J., Valaa W.E. and Johnston J.K. (1999). Caesarean section and other methods for assisted delivery: comparison of effects on mare mortality and complications. *Equine Vet.J.* **31**, 203-207.
- 400 Giles R.C., Donahue J.M., Hong C.B., Tuttle P.A., Petrites-Murphy M.B., Poonacha K.B., Roberts A.W., Tramontin R.R., Smith B. and Swerczek T.W. (1993). Causes of abortion, stillbirth and perinatal death in horses: 3,527 cases (1986-1991). *J.Am.Vet.Med.Ass.* **203**, 1170-1175.

- 405      Ginther O.J., Williams D. (1996). On-the-farm incidence and nature of equine dystocias. *J. Equine Vet. Sci.* **16**, 159-164.
- Govaere J., Hoogewijs M., De Schauwer C., De Vlieghe S., Saey V. and A de Kruif (2008). Lack of association between low vitamin E levels and retention secundinarum in Belgian draught Horses (BDH) and Warmblood (WB) mares. *Reprod Dom Anim* **43**, 105.
- 410      Govaere J., A. de Kruif and Valcke M. (2010). Differential impact of unguided versus guided use of a multimedia introduction to equine obstetrics in veterinary education. *J Vet Med Educ* submitted.
- Govaere J., Martens K., de Kruif A. (2010b). The FoalinMare. Insights inside the foaling mare. Eds J.Govaere, Ghent University Belgium
- 415
- Hackett R., Vaughan J., and tenant B. (1982). Prolaps of the urinary bladder. In: Equine Medicine and Surgery, Eds: R. Mansmann, E.McAllister and P.Pratt, American veterinary Publications, Santa Barbara. p 920.
- Hance S.R. and Embertson R.M. (1992). Colpey in broodmares – 44 cases (1986-1990). *JAVMA* **201**, 782-787.
- 420      Honnas C.M., Spensley M.S., Lavery S. and Blanchard P.C. (1988). Hydramnios causing uterine rupture in a mare. *JAVMA* **193**, 334-336.
- Jeffcott L.B. (1974). Some practical aspects of the transfer of passive immunity to newborn foals. *Equine Vet. J.* **6**, 109-115.
- Jeffcott L.B., Rosedale P.D. (1977). A critical review of current methods for induction of parturition in the mare.
- 425      *Equine vet J* **9**, 208-215.
- Jeffcott L.B., Rosedale P.D. (1979). A radiographic study of the fetus in late pregnancy and during foaling. *J. Reprod. Fert. Suppl.* **27**, 563-569.

- Johnston J.K. and Freeman D.E. (1997). Diseases and surgery of the large colon. *Vet. Clin.N.Am-Equine Pract* **13**, 317
- 430 Krustritz, M.V.R., Chenoweth, P.J., Tibary A. (2006). Efficacy of training in theriogenology as determined by a survey of veterinarians. *Journal of veterinary Medical Education* 229(4), 514-521.
- Leadon D.P., Jeffcott L.B. and Rossdale P.D. (1984). Mammary secretions in normal spontaneous and induced premature parturition in the mare. *Equine vet J* **16**, 256-259.
- Leadon D.P., Jeffcott L.B. and Rossdale P.D. (1986). Behavior and viability of the premature neonatal foal after  
435 induced parturition. *Am J Vet Res* **47**, 1870-1873.
- LeBlanc M.M., Norman W.E. (1992). Sedation and anesthesia of the mare during obstetric manipulation. *Proc.Am.Ass.Equine Pract.* **38**, 619-622.
- Ley W.B., Hoffman J.L., Crisman M.V., Meacham T.N., Kiracofe R.L. and Sullivan T.L. (1989). Daytime foaling management of the mare.2. induction of parturition. *J Equine Vet Sci* **9**, 95-99.
- 440 Ley W.B., Bowen J.M., Pursewell B.J., Irby M. and Creivecrandell K. (1993). The sensitivity, specificity and predictive value of measuring calcium carbonate in mares prepartum mammary secretions. *Theriogenology* **40**, 189-198.
- Livesey M.A. and Keller S. (1986). Segmental ischemic necrosis following mesocolic rupture in post-parturient mares. *Compend Contin Educ Pract Vet* **8**, 763-768.
- 445 Lopate C., LeBlanc M., Pascoe R., Knottenbelt D. (2003). Parturition. In *Equine Stud farm Medicine and Surgery*. Knottenbelt DC, LeBlanc M, Lopate C., Pascoe R.R. Saunders, Edinburgh pp 269-324.
- Martens K.A., Govaere J.L.J., Hoogewijs M.K., Lefevre L., Nollet H., Vlaminck L., Chiers K., de Kruif A. (2008). Uterine torsion in the mare: a review and three case reports. *Vlaams Diergeneesk Tijdschr* **77**, 397-405.

- 450 Ousey J.C., Dudan F. and Rossdale P.D. (1984). Preliminary studies of mammary secretions in the mare to assess foetal readiness for birth. *Equine Vet. J.* **16**, 259-263.
- Ousey J.C., Delclaux M. and Rossdale P.D. (1989). Evaluation of three strip tests for measuring electrolytes in mares' prepartum mammary secretions and for predicting parturition. *Equine Vet. J.* **21**, 196-200.
- Pascoe J.R., Meagher D.M. and Wheat J.D. (1981). Surgical management of uterine torsion in the mare: a review of 26 cases. *J.Am.Vet.Med.Ass.* **179**, 351-354.
- 455 Peaker M., Rossdale P.D., Forsyth I.A., and Falk M. (1979). Changes in mammary development and composition of secretion during late pregnancy in the mare. *J Reprod fertile Suppl* **27**, 555-561.
- Perkins N.R., Frazer G.S. (1994). Reproductive emergencies in the mare. *Vet Clin N Am –Equine Practice* **10**, 643-670.
- 460 Provencher R., Threfall W.R., Murdick P.W. and Wearl W.K. (1988). Retained fetal membranes in the mare-a retrospective study. *Can Vet J* **29**, 903-910.
- Renton J. (1984). Parturition in the mare. *In Pract* **6**, 19-21
- Roberts S.J. (1986). Veterinary obstetrics and genital diseases (Therigenology), 3re edn. Woodstock, VT, pp 298-307.
- 465 Rossdale P.D. (2003). Differential diagnosis of post parturient haemorrhage in the mare. *Equine Vet. Educ.* **15**, 48-50.
- Rossdale P.D., Ricketts S.W. (1980). Birth: Equine stud farm medicine, 2<sup>nd</sup> Ed., Lea&Febiger, Philadelphia, Pa, pp 220-276.
- Schmid G., Stolla, R., Leidl, W. (1994). Particularités obstétricales chez le cheval. *Revue Médecine Vétérinaire* **145(2)**115-118.

- 470 Semacan A., Baspinar N., Tekeli T., demirel M. and Kurdoglu F. (1999). Predicting the foaling time by measuring the electrical conductivity and electrolyte contents of the prepartum mammary secretion. *J. Equine Vet.Sc.* **19**, 81-83.
- Sevinga M., Barkema H.W., Stryhn H. and Hesselink J.W. (2004). Retained placenta in Friesian mares: incidence and potential risk factors with special emphasis on gestational length. *Theriogenology* **61**, 851-859.
- 475 Ueno T., Nambo Y., Tajima Y. and Umemura T. (2010). Pathology of lethal peripartum broad ligament haematoma in 31 Thoroughbred mares. *Equine Vet J* doi:10.1111/j.2042-3306.2010.00090.x .
- Vandeplassche M. (1980). Obstetricians view of the physiology of equine parturition and dystocia. *Equine Vet. J.* **12**, 45-49.
- Vandeplassche M. (1993). Dystocia. In: *Equine Reproduction*. Eds: A.McKinnon and J.Voss, Lea and Febiger, Philadelphia. Pp 578-587.
- 480
- Villani M., Romano G. (2008). Induction of parturition with low-dose oxytocine injections in pregnant mares at term. Clinical applications and limitations. *Repr Dom Anim* **43**, 481-183.
- Wheat J.D., Meagher D.M. (1972). Uterine torsion and rupture in mares. *JAVMA* **160**, 881-
- Whitwell K.E., Jeffcott L.B.(1975). Morphological studies on the fetal membranes of the normal singleton foal at
- 485 term. *Res.Vet. Sci.* **14**, 44-55.